

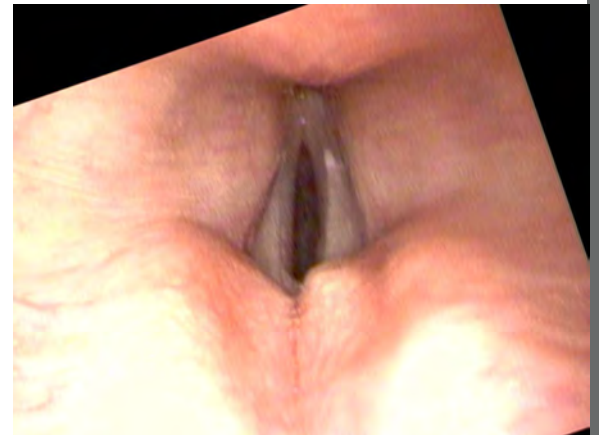
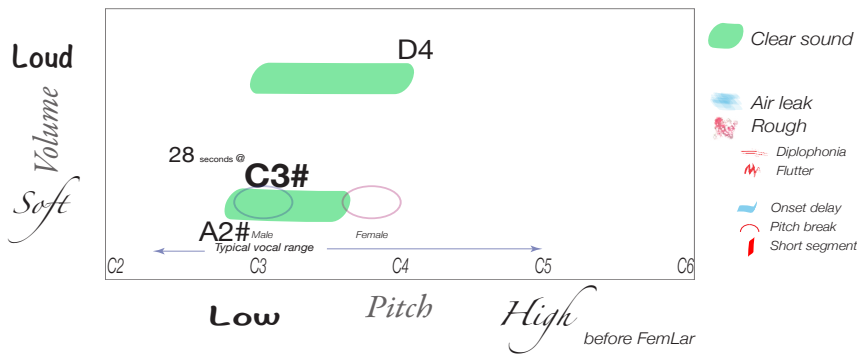
FEMINIZATION LARYNGOPLASTY

SURGICAL CREATION OF A
FEMININE VOICE

JAMES P. THOMAS, M.D.
VOICEDOCTOR.NET/SURGERY/PITCH

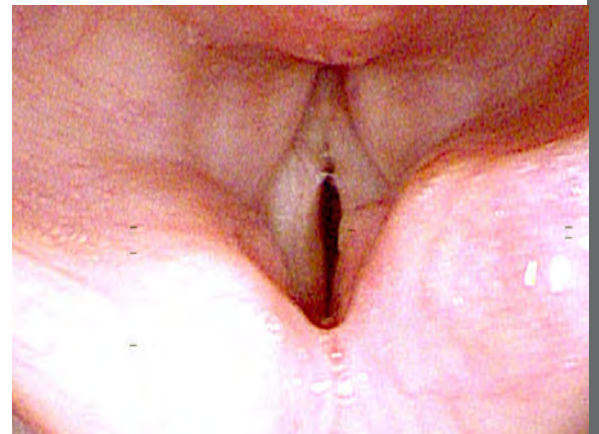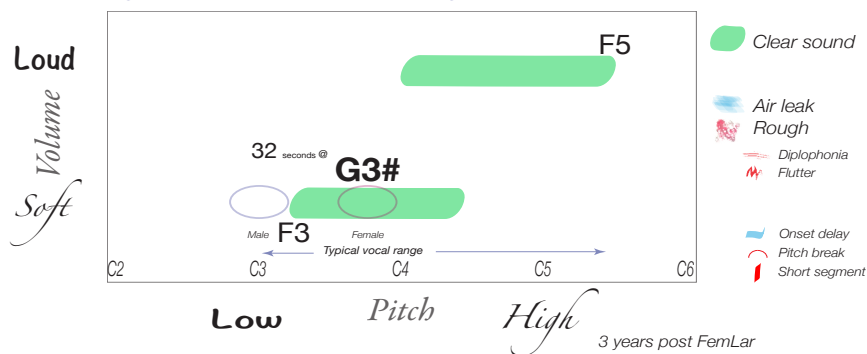
BEFORE

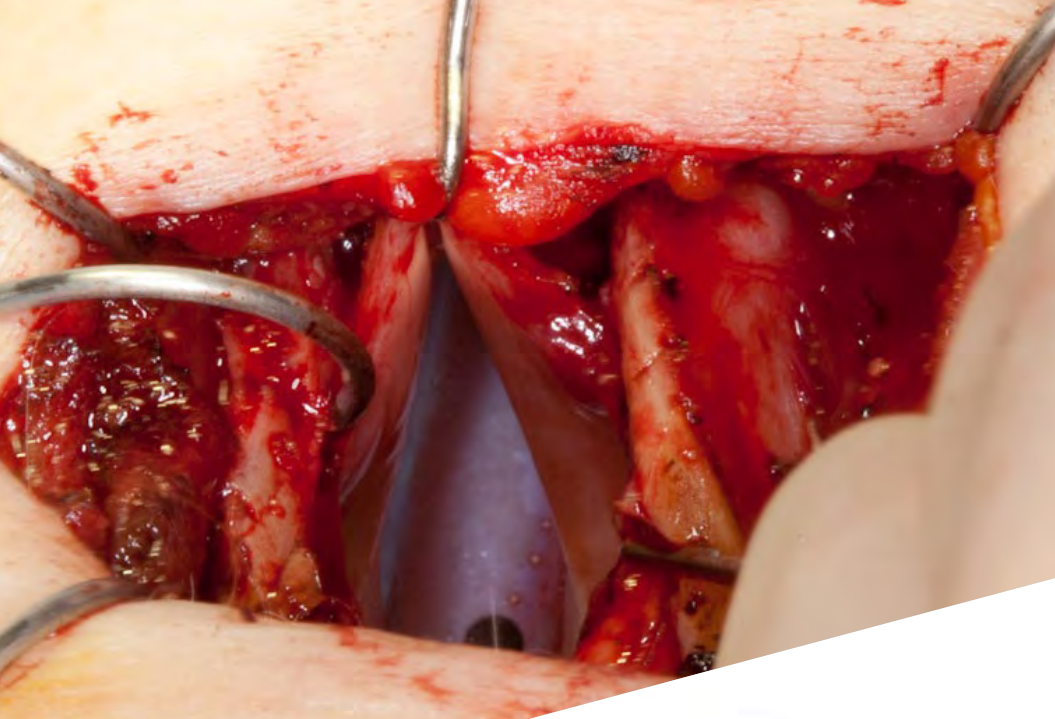
Laryngeal Acoustic Testing - Vocal capabilities



AFTER

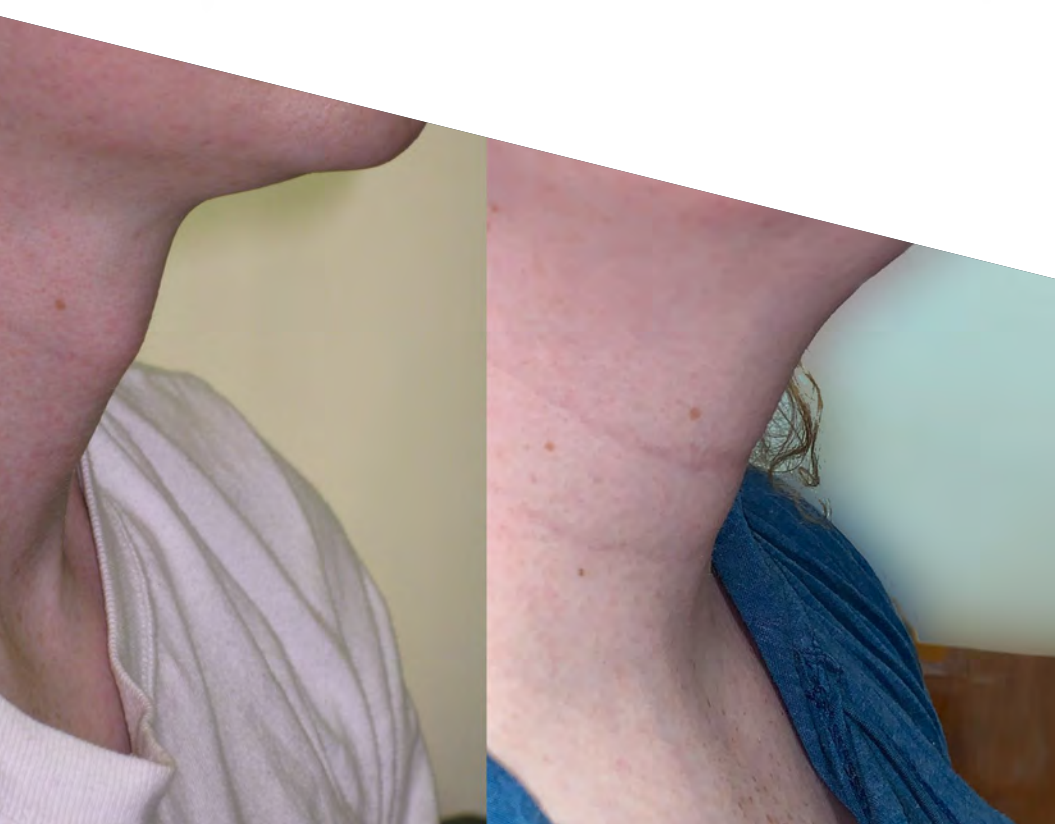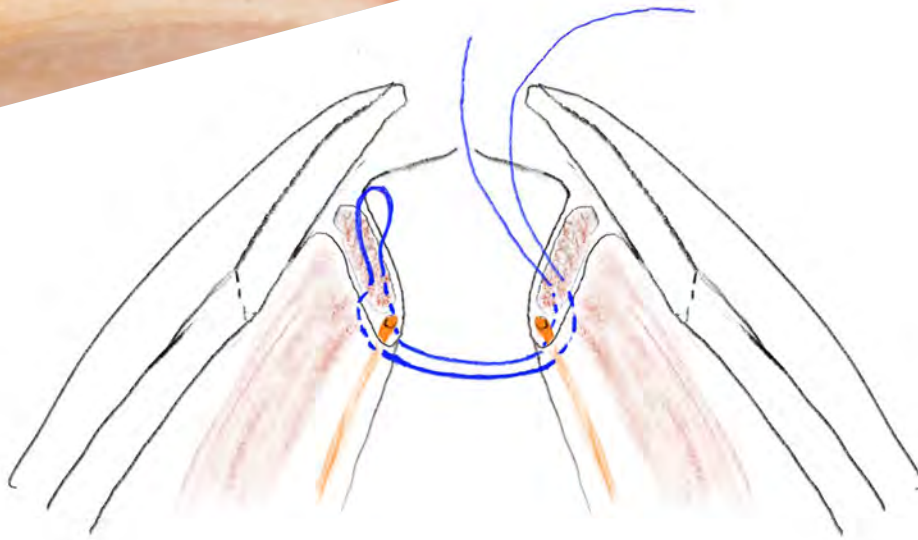
Laryngeal Acoustic Testing - Vocal capabilities





SUMMARY

- 3 Feminization Laryngoplasty overview
- 4 Testosterone
- 5 Faculty - James P. Thomas, M.D.
- 6 Surgical options
Indications for surgery
- 7 Pre-Operative
Day of Surgery
- 8 Incision
- 9 Upper thyroid alae removal
- 10 Narrowing the glottis
- 11 Entering the airway
- 12 Narrowing the supraglottis
- 13 Marking sutures
- 14 True Cord excision
- 15 Reconstructing the anterior commissure
- 17 Thyroarytenoid muscle tension
- 19 Vocal Cord Tensioning
Thyrohyoid Elevation
- 21 Postoperative care
Caveats
- 23 Bibliography
- 24 Conclusions



James P. Thomas, MD
909 NW 18th Avenue
Portland, OR 97209 - USA

voicedoctor.net
thomas@voicedoctor.net
+1 503 341-2555

April 2026 edition

FEMINIZATION LARYNGOPLASTY

Feminization Laryngoplasty evolved from the aim to change a larynx from a male structure to a more female structure. This would in theory raise both the fundamental frequency of the voice and the resonant frequency of the vocal tract, particularly for male-to-female transgender patients. It is designed in an attempt to address possible shortcomings in quality, longevity, as well as complications of existing procedures (vocal webbing, cricothyroid approximation, laser reduction). This paper explores the reasoning behind and the evolution of the Feminization Laryngoplasty procedure.

Methodology: Feminization Laryngoplasty consists of:

- 1 removing of the anterior thyroid cartilage to collapse the diameter of the larynx with the added benefit of removing the protruding profile of the Adam's Apple more extensively than the existing procedure of "Tracheal Shave".
- 2 removing the anterior vocal cords to shorten, possibly thin and tension the vocal cords with the goal of raising the comfortable speaking pitch.
- 3 shortening the false vocal cords narrowing the supraglottis, possibly altering resonance.
- 4 removing the superior portion of the thyroid cartilage, shortening the vertical dimension of the larynx and suspending the larynx higher in the neck via thyrohyoid elevation. The goal is internally shortening the pharyngeal chamber, altering resonance towards more feminine overtones.

Feminization Laryngoplasty may be used as an approach to reattach and retighten vocal cords after the complication; vocal cord detachment, which may occur as a complication during a "Tracheal Shave."

Post-intervention the vocal cords may be tuned further with additional procedures such as office KTP laser tightening or operative CO2 laser debulking.

Risks: Risks and limitations of the procedure include the need for an external incision, potential infection and airway compromise in the immediate postoperative period. Upper limits of the vocal range may be lowered and the upper range may have a tighter quality. Uneven tension may cause roughness of the voice requiring additional procedures. Comfortable speaking volume and maximum volume tend to be reduced.

The problem: testosterone

Once exposed to testosterone, often during puberty, the thyroid cartilage enlarges, both increasing the internal luminal size of the larynx as well as altering the neck profile by visible protrusion of the Adam's Apple. The vocal cords elongate and thicken, lowering the comfortable speaking pitch and lowest vocal pitch. There is usually a reduction of the upper vocal range or at least a change in the quality of the upper vocal range since thicker vocal cords must be stretched tighter to produce the same pitch. The relaxed laryngeal position drops lower in the neck increasing the internal length of the pharyngeal chamber; a longer chamber selectively amplifying the lower notes. Even genetic females taking exogenous hormones, testosterone for libido or anabolic steroids for bodybuilding, often leads to masculinization of the laryngeal structures.

In individuals identifying as female gender (whether genetically male, intersex or female), speech therapy or self-practice may result in learning to produce a desirable speaking vocal pitch and resonance, masking these changes induced by testosterone. These techniques utilize active compensatory muscle contraction of intrinsic and cervical muscles and require ongoing effort. Some individuals are successful in developing a habitual contraction, to the point of requiring conscious effort to lower their larynx and speak with their "male voice" while perhaps most others develop ongoing fatigue from these attempts at maintaining female pitch and resonance through tonic muscle contraction. Some individuals are unable to accomplish this task at all. Even when successful, most individuals remain fearful of letting their guard up for even a moment in a sensitive situation where a masculine voice would be inappropriate.

If success is defined as the ability to sound feminine in controlled situations, then speech/voice therapy offers a low-complication, high time-investment, approach to feminizing the voice. For the individual who defines success as the inability to sound masculine, then speech therapy fails 100% of the time.

As an ideal, after some intervention, comfortable speech would occur at a feminine pitch and with a feminine quality without having to think before every phonation.

When surgery is successful, no further

intervention, such as speech therapy is needed. However, other than a time and monetary investment, speech therapy generally does no harm and in cases where surgery is not completely successful, speech therapy may offer an adequate supplement to create a convincing feminine voice.

The fundamental frequency of speech is only one distinctive parameter in determination of a male versus female voice [1,2]. A number of pitch-altering surgeries have been pursued to address this frustration including cricothyroid approximation (CTA) [1 - 8], anterior commissure advancement [9] vocal cord webbing [10 - 12] and laser tightening (LAVA) [14].

CTA was one of the most common surgeries used to change the comfortable speaking pitch of the voice in the 1990 - 2010 period. The normal action of the cricothyroid muscle is to lengthen the vocal cord [13]. The vocal quality produced by this increase in tension of the vocal cord is called falsetto. Bringing the thyroid cartilage and cricoid cartilage into approximation in the anterior midline, CTA surgery effectively sutures the cricothyroid muscle into a permanent position of contraction, permanently lengthening the true vocal cord, although the degree of residual vocal cord tension is variable.

Some of the positive attributes of CTA surgery include the following. It is relatively easy to perform the surgery with the anatomy located very close beneath the skin. Surgeons inexperienced with the procedure can perform it relatively well.

There is minimal discomfort with the procedure and it may be performed under local anesthesia. The patient may speak during the procedure if the surgeon has a desire to attempt to "tune" the pitch during the procedure, although for many "CTA surgery is typically performed with intentional hyper-elevation of pitch in anticipation of gradual relaxation of the induced vocal fold tension over time" [14]. Because it is relatively easy to perform, relatively safe from acute surgical complications and can be performed in a relatively short time, surgical costs associated with the procedure are medically low.

I began performing CTA surgery in 2001 for male to female transgender patients wishing to speak comfortably at a higher pitch in day-to-day conversation. I reviewed results

on 23 patients in 2003 for a presentation (Thomas, J.P. Cricothyroid approximation & other phonosurgical procedures to alter the transgender voice. Biennial meeting of the Harry Benjamin International Gender Dysphoria Association, Inc. (HBI-GDA), September 12, 2003, Ghent, Belgium). I noted that in aggregate, there was elevation of the comfortable speaking pitch by 7 semitones, although this ranged from a lowering of the speaking pitch by two semitones in one patient to an elevation of pitch by 18 semitones in one patient. The range was wide and seemingly unpredictable. To most patient's relief, individuals also lost an average of 9 semitones from the bottom of their speaking range, providing a speaking pitch not at risk for a sudden drop in pitch.

Significant issues though were noted with the CTA procedure. Some patients experienced an initial pitch elevation that faded back to a baseline pitch over a few months, ultimately experiencing no permanent change in their comfortable speaking pitch. This occurred in about one third of patients despite vocal cords that remained visibly stretched on endoscopy. Neumann et al also noted about one third of patients had a neutral pitch and about one third failed to gain in pitch [15]. During attempted surgical revisions on my own patients and on others, where a variety of sutures and a variety of suture placement techniques were utilized, I noted no cricothyroid suture failure. The cricothyroid space remained ablated, typically with the cricoid and thyroid cartilage fused in the anterior midline. I noted various suturing techniques including metal sutures, bolstered sutures, single or multiple sutures and none of the sutures had pulled out. Internally, during quiet respiration, the vocal process and membranous vocal cord margins were parallel in alignment, a position typically only seen continuously when the cricothyroid muscle is contracted. Yet patients appeared to have lost pitch elevation by losing internal membranous vocal cord tension.

Another problematic issue with patients undergoing CTA surgery is that many patients with successful pitch elevation spoke with an unnatural, hyper-elevated pitch ranging from an extreme falsetto to a mild falsetto quality of their voice. For some surgeons, "CTA surgery is typically performed with intentional hyper-elevation of pitch in anticipation of gradual

relaxation of the induced vocal fold tension over time” [14]. Some of my patients describe this as a “gay male” sound.

My experience during revision surgery is that the cricoid and thyroid cartilages frequently fuse in the anterior midline after CTA surgery. Even when separated though, the patient does not typically regain control over their falsetto range. My suspicion is that the cricothyroid joints ankylose after a period of immobilization.

I have observed an uncommon problem related to the cricothyroid joint. The joint appears may become fixed, perhaps subluxed, such that an individual may almost completely lose the ability to change pitch and volume at all, leaving them with a monotonal voice.

Even when successful for a change in comfortable speaking pitch, a post CTA patient forfeits the use of her cricothyroid muscles. Tensioning the thyroarytenoid muscle must now regulate the entire pitch range. Because I felt these issues were significant vocal compromises for gender transitioning patients, I looked for an alternative approach that would raise the comfortable speaking pitch.

There are various types of lasers and various modalities for using lasers on the vocal cords. One type of laser treatment, LAVA, attempts to increase vocal pitch through a thinning and tightening of the vocal cords. Increases in fundamental frequency with this technique tend not to be as large as with other surgical methods [14]. One advantage is that no external incision is required. In one of my patients whose pitch spontaneously returned to the

masculine range after CTA, the addition of the LAVA procedure brought her comfortable speaking pitch back up toward the female range again temporarily. So it is possible that some combination of procedures might be beneficial. See also [16].

A proposed fundamental frequency range for adult females is 145-275Hz (D3-C#4) and for males is 80-165Hz (D#2-E3) [16]. This leaves an area of overlap from 145-165Hz (D3-E3) where fundamental frequency alone might not be sufficient to determine the sex of a patient. This is important as transgender patients with Fo as high as 181Hz have been perceived as male. “It appears that it is the interaction between Fo, Fo range, intonation and resonance that ultimately determines the perception of the speaker as female” [17]. Addressing these components as complements to each other would represent a more desirable approach to voice modification compared to fundamental pitch change alone.

Resonant frequency affects the gender perception of voice. This is especially true in the gray area where normal male and female speaking pitches overlap [18]. The resonant frequency is inversely related to the length of the resonant tube, the pharynx [19]. Speech therapy techniques have been used to modify the mouth opening and tongue placement [17]. Gunzburger noted that when comparing transsexuals’ male vs. female voice the resonance patterns change [20]. He hypothesized that this was accomplished by practiced manipulation of oropharyngeal shape and the elevation of the larynx [2, 20].

Elevation of the larynx enables higher resonant frequency of the pharynx, as the length of the resonant tube is decreased [21].

In transgender patients particularly adept at creating a female voice quality, I note an ability to maintain with muscle tension two pharyngeal parameters: elevation of the larynx and narrowing of the pharynx. Based on a personal communication with Robert Bastian discussing this idea, I began to suspend the larynx higher in the neck (thyrohyoid elevation component). This might address one of the parameters, length of the pharyngeal chamber, leaving to the patient to address the diameter of the chamber with muscle contraction if possible.

I have tried to reduce the diameter of the pharyngeal chamber in a few patients by resecting a vertical strip of pharynx, either centrally or two strips laterally, but I have not yet worked out a reliable technique to accomplish narrowing.

Somyos Kunachak in Thyroid Cartilage and Vocal Fold Reduction [22] proposed an open laryngoplasty to alter pitch. This procedure reduced the size of the larynx to a more female size in its cross sectional dimension and shortened the length of the vibratory vocal fold. It possibly tensioned the vocal fold. It preserved the use of the cricothyroid muscle. Perhaps it thinned the vocal folds. Based primarily on this article, I began to perform what developed into a procedure termed Feminization Laryngoplasty or as my first patient called it, “FemLar.”

INTRODUCTION

Author...

JAMES P. THOMAS, MD



Specializing in voice disorders since 1998 has tuned my ear to vocal subtleties. Feminization of the human voice is a pathway I have explored during that time and this publication is a summary of where my thoughts and learning have led.

OPTIONS

Surgical

Perception of femininity is related to pitch and resonance

1. Pitch is determined by mass / length / tension of the vibrating edge
2. Resonance relates to supraglottic chamber area

Potential surgical tools for altering pitch and resonance

- 1) Cricothyroid approximation
 - increase tension & length of vocal cords
 - lose a pitch tensioning muscle (cricothyroid muscle)
- 2) Laser reduction / tightening (CO2 or KTP)
 - reduce mass
 - thyroarytenoid muscle
 - tighten vibratory margin
 - vocal margin height (if very careful)
- 3) Glottoplasty / webbing
 - shorten vibrating length
- 4) Laryngoplasty (feminization)
 - shorten length
 - maintain tension
 - reduce mass per unit length by stretching
 - alter resonance (narrow supraglottis)
- 5) Thyrohyoid elevation
 - reduce vertical height of pharynx
- 6) Pharyngoplasty (narrowing)

These procedures are not exclusive to each other. More than one may be used on an individual. My protocol is to perform Feminization Laryngoplasty including Thyrohyoid elevation initially. Then I consider touching up the voice with one of the lasers as a secondary procedure.

Similarly, an individual who has had an incompletely successful webbing procedure may benefit from an additional laser procedure rather than a revision webbing that shortens the vocal cord margin too much.

An individual with a completely failed webbing procedure can often undergo a Feminization Laryngoplasty without much difficulty.

Cricothyroid approximation is the most difficult procedure to deal with failures. An important muscle for pitch elevation is lost. The cricothyroid joint is usually non-functional, even after any revision procedures. Secondary procedures are not as successful as other primary procedures. Pitch range typically becomes extremely limited.

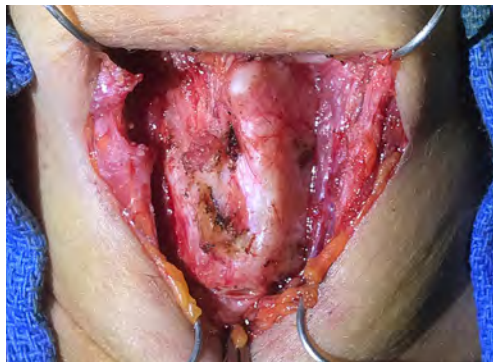
PRE-OPERATIVE

Indications

DESIRE FEMINE VOICE

The most common indication is a desire to have a comfortable female voice. Generally that is assessed as the ability to sound feminine naturally on the telephone. This is addressed by altering the comfortable speaking pitch.

Related to this is the desire to lose the capacity to produce male sounds inadvertently. This is addressed by removing low pitch sound production and altering resonance upward.



FAILING VOICE THERAPY

An individual does not need to fail voice therapy to undergo surgical voice feminization, but an individual with poor vocal rapport has a more palatable risk:benefit ratio. If one cannot sound feminine at all after therapy, then surgical approaches offer a benefit not even possible with therapy.

TRACH SHAVE COMPLICATION

Detachment of the anterior commissure occurs to varying degrees when portions of the anterior thyroid cartilage are removed. This is the only method I know of for reattachment and retensioning of true vocal cords which have been loosened.

PRE-OPERATIVE

Recording the voice

PRE OPERATIVE

After an appropriate history, the patient's voice is documented based on <https://www.voicedoctor.net/diagnosis/examination/optimal-exam>. This begins reading a standardized passage. I often start with attempted best female voice but then also record the comfortable speaking pitch (or "old voice" if the patient is quite feminine proficient). Vocal pitch range, maximum and minimum volumes, maximum phonation time and vegetative sounds are recorded. The vocal cords are then visualized and video

recorded with flexible laryngoscopy including stroboscopy at a variety of pitches and volumes. This documents the voice for any postoperative comparison.

Surgical and non-surgical alternatives are discussed. This includes possible risks for each type of surgery and therapy, both immediate risks such as infection and swelling as well as long term risks such as volume reduction, roughness, singing limitations, etc.

Patients attend a one-hour voice education discussion with a voice therapist prior to surgery.

OPERATIVE

Day of surgery

SURGERY

Location: Surgery is performed in a Medicare certified, outpatient surgical center.

Anesthesia: General endotracheal anesthesia, typically using a 6-0 endotracheal tube. The procedure is typically under two hours duration.

Antibiotics: All patients are given clindamycin along with either a third generation cephalosporin (cefotaxime - Claforan) or fluroquinolone (levofloxacin - Levaquin) at the beginning of the case. 600 mg of clindamycin is administered IV over 10 minutes. The other drug is also given IV before the incision.

Near the end of surgery, the wound is irrigated with normal saline containing 100,000

units per liter of bacitracin prior to closure.

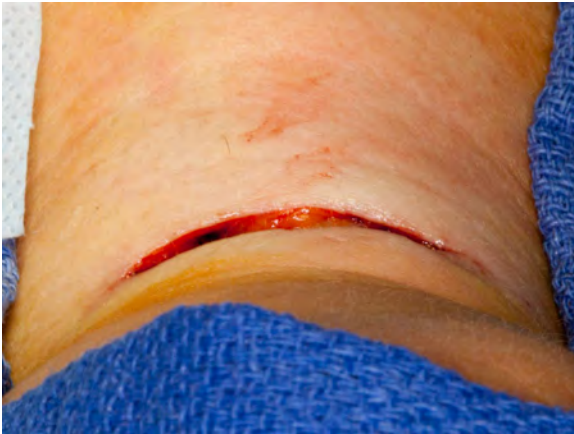Because of the seriousness of airway swelling in the supraglottic region, I also give 7 days of post-operative oral therapy with either cefuroxime or levofloxacin (choosing based on on patient reported allergies and drug availability).

Early in my series of patients I was administering Clindamycin and Gentamycin without postoperative antibiotics. In two cases, postoperative wound infections led to supraglottic swelling that required a temporary tracheostomy. That has not occurred since the above changes in antibiotic administration.

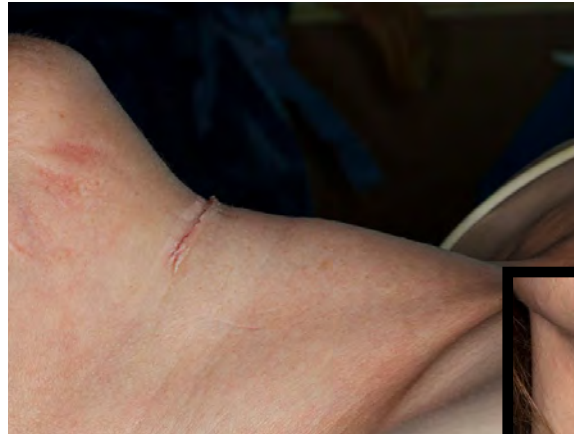Steroids: 10 mg of dexamethasone are given intravenously at the beginning of surgery. Oral prednisone or methylprednisolone are given in selected cases if significant swelling develops postoperatively.

TECHNIQUE

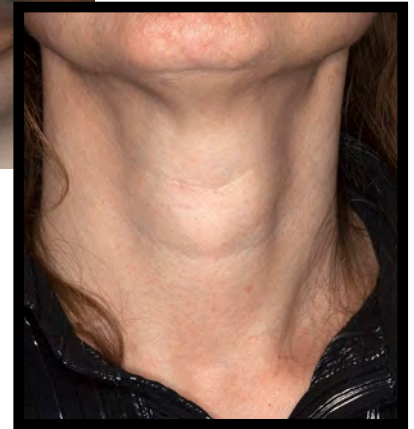
Incision



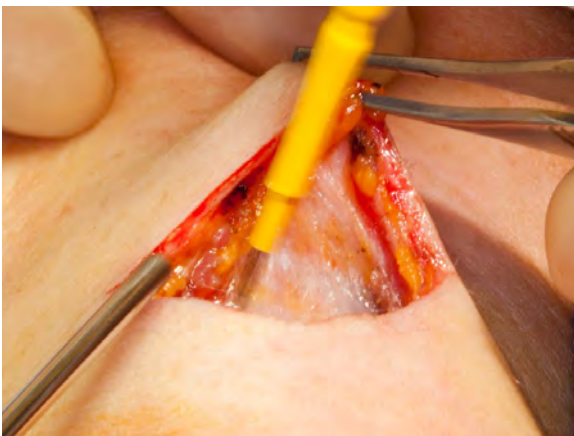An approximately 5 cm incision is placed in or parallel to a skin crease directly in the midline. The incision should be designed to easily reach from the cricothyroid membrane inferiorly to the hyoid bone superiorly. A longer incision allows easy reach and still looks cosmetically good if placed into a skin crease. If the incision is too high, rendering view of the vocal cords difficult, then tears in tissue or errors in placement of the important and delicate vocal cord sutures may be more common. An incision in a skin crease is more difficult to see later than a higher incision in or near the submental area that crosses skin tension lines.



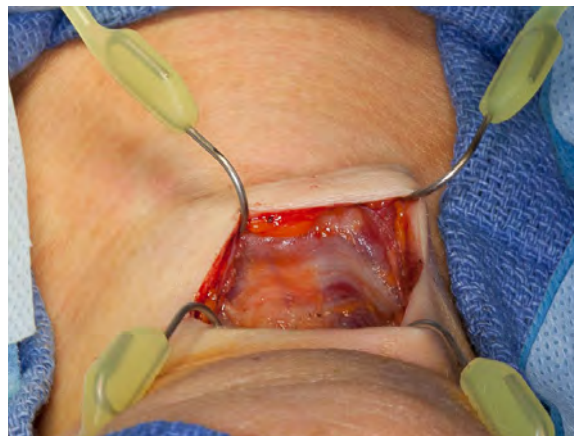Here I chose the upper of two prominent skin creases (view at the end of surgery so thyroid cartilage prominence is removed. Remaining prominence inferior to lower skin crease is the cricoid cartilage).



An incision 1 year post surgery.



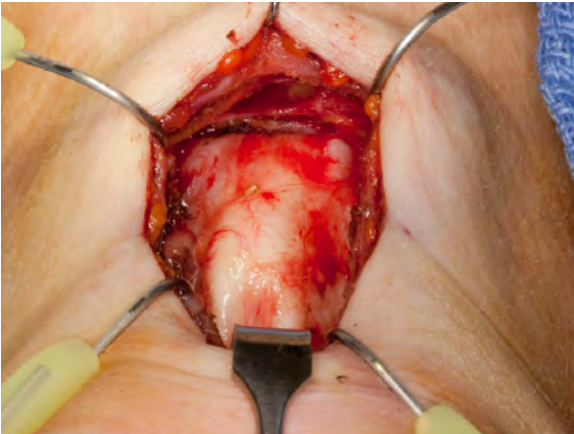Superior and inferior flaps are developed at a level beneath the platysma.



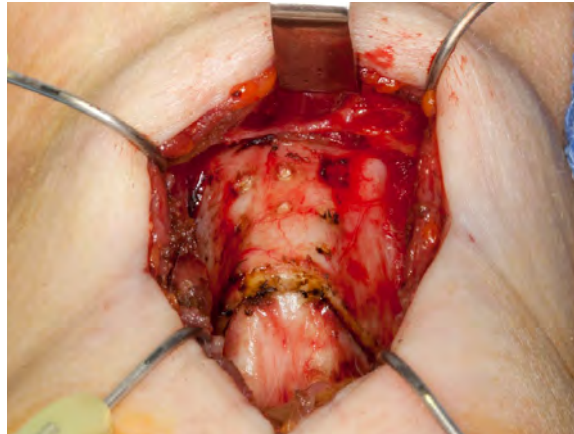
I use a Lone Star® retractor system for exposure. Strap muscles are visible on either side of the thyroid cartilage.

TECHNIQUE

Upper thyroid ala removal

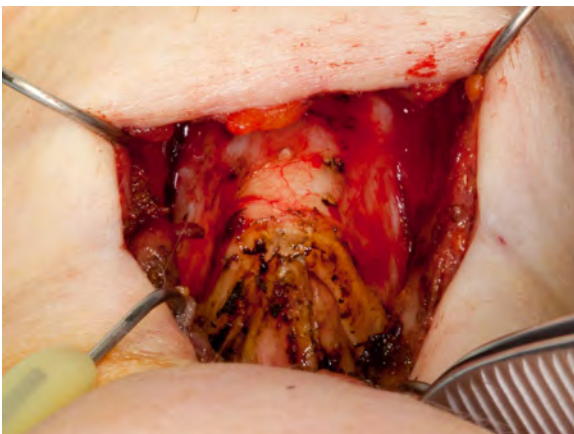


Strap muscles are separated in the midline exposing anatomy from the hyoid bone to the upper cricothyroid membrane. Lateral dissection extends to the insertion of the thyrohyoid muscle onto the thyroid cartilage. The inferior border of the thyroid cartilage is superficially separated from the cricothyroid membrane. There are frequently small arteries in the lateral portion of this area.



The midline is marked with a Bovie cauterium and secondary marks are placed 3-4 mm lateral to the midline on each side. I have gone as wide as 8 mm, but it can then be difficult to close the thyroid cartilage in the midline as it abuts against the cricoid ring internally.

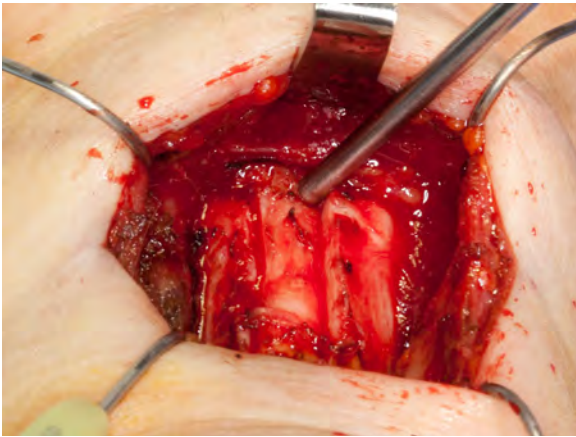
I have also marked the upper thyroid cartilage incision to remove the upper alae of the thyroid cartilage, usually about 10 mm in tallest vertical dimension.



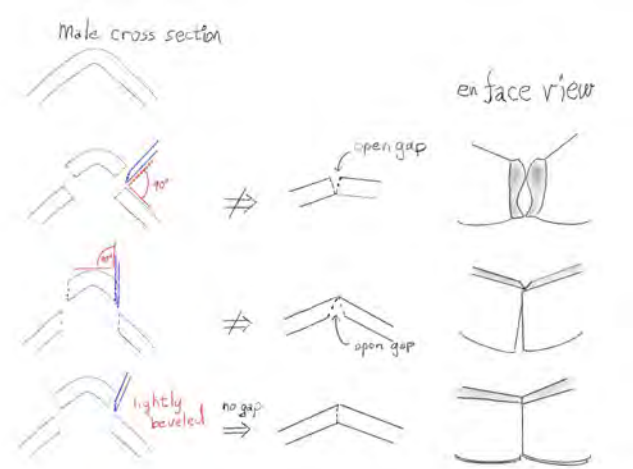
In young patients, the upper alae may be removed with a knife or cauterium. In older patients, this is calcified and a saw is used to cut through the ossified thyroid cartilage.

TECHNIQUE

Central strut removal Narrow glottic diameter



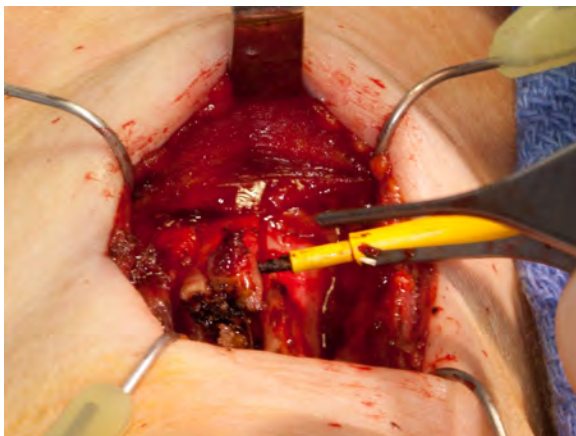
The thyroid cartilage is divided vertically with an oscillating saw on either side of midline with the saw kerf removing about one additional millimeter of cartilage. The goal is to narrow the internal aperture of the laryngeal glottis by collapsing the thyroid alae medially.



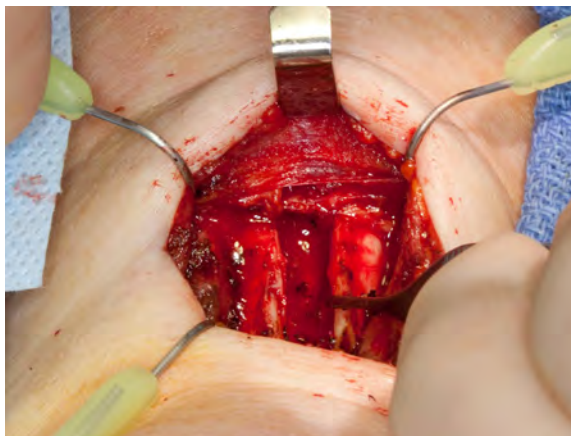
Saw cuts which are slightly beveled will allow an airtight closure of the thyroid cartilage in the midline.

If the saw cuts are perpendicular to the surface of the cartilage, then the inner table which is irregular in contour will abut first and large gaps will prevent an airtight closure.

If the saw cuts are parallel to the coronal axis, then the outer table will close first leaving an internal gap - not as problematic, although the midline closure will not be as stable and one side may try to override the other.



With electrocautery, the strip of anterior thyroid cartilage is elevated away from the inner thyroid perichondrium and removed. The airway is not typically entered, though if it is, penetration usually occurs in the thinnest area, which is just superior to the anterior commissure.



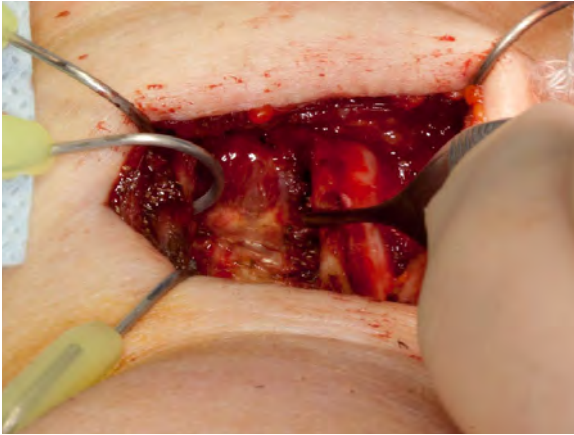
This removal of the vertical internal thyroid cartilage segment will allow narrowing of the internal laryngeal aperture and very effectively removes the Adam's Apple contour (more completely than a "tracheal shave").

CAUTION:

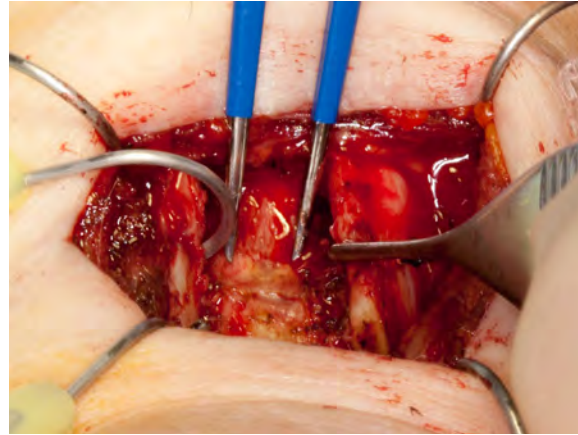
The endotracheal tube cuff needs to be positioned inferior to the cricoid cartilage. If it is inflated in the subglottis, the saw will incise the inner thyroid perichondrium and rupture the cuff, necessitating a tube replacement and a repair of the lacerated airway.

TECHNIQUE

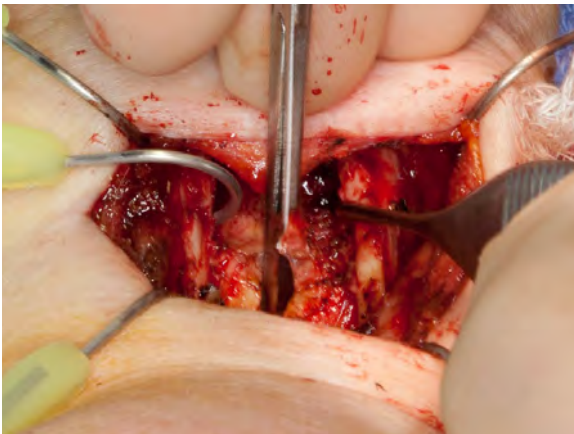
Entering the airway



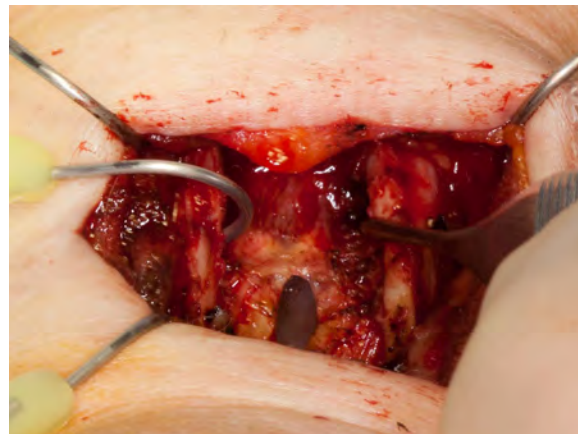
Cauterizing a number of small bleeding vessels and retracting the thyroid alae laterally exposed the inner perichondrium, often still intact..



The anterior glottic ligaments of the anterior commissure are usually visible through the perichondrium. Here the bipolar forceps are pointing to the ligaments.



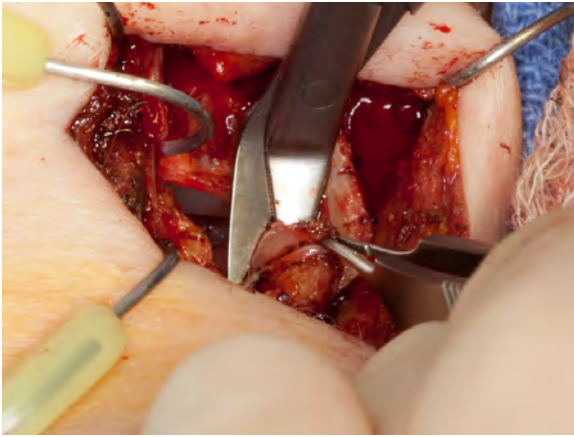
The airway is vertically incised just superior to the anterior commissure. I extend this midline incision superiorly through the anterior commissure of the false vocal cords.



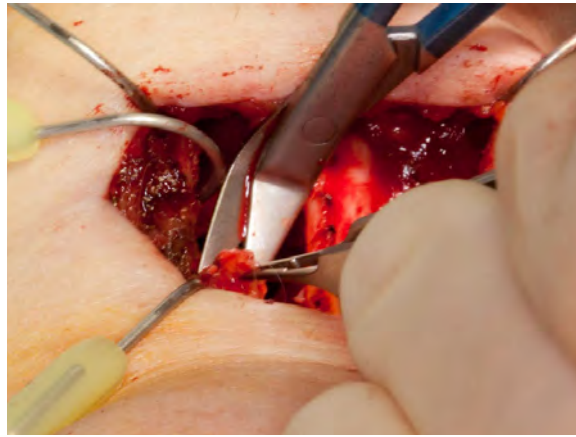
Through the opening is a view of the endotracheal tube and the true vocal cords from above.

TECHNIQUE

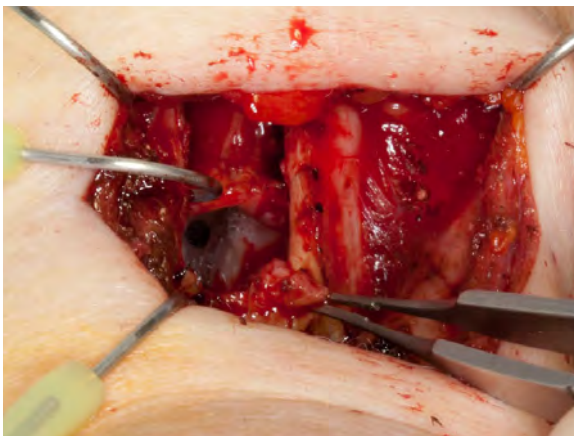
Narrow supraglottis False cord resection



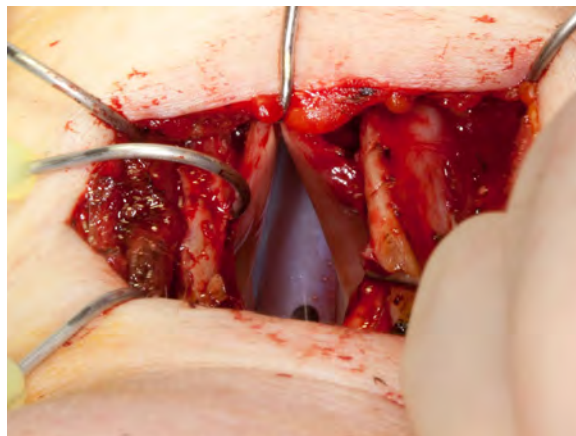
Placing the right false vocal cord on a stretch, the anterior 5 mm of the false cord is excised, likely including the saccule. This reduces the diameter of the supraglottis after surgery. During surgery, this also provides an improved view of the true vocal cords and more space to manipulate needles within the larynx.



A similar amount of left false vocal cord is excised.

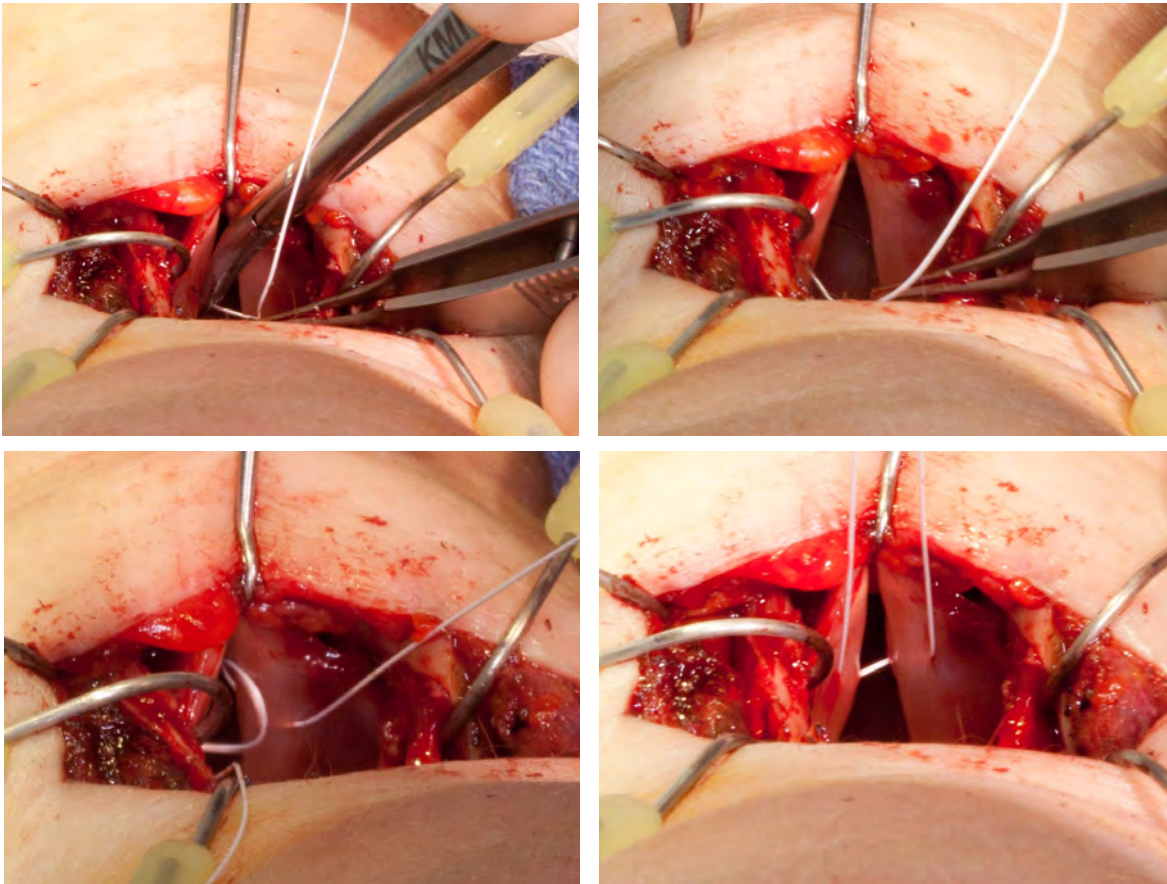


Maintain the anterior glottic ligament intact in order to pull symmetrically on the vocal cords with a hook. Assess how much of the anterior vocal cord needs to be removed in order to collapse the thyroid alae back into the midline while maintaining tension on the vocal cords.



TECHNIQUE

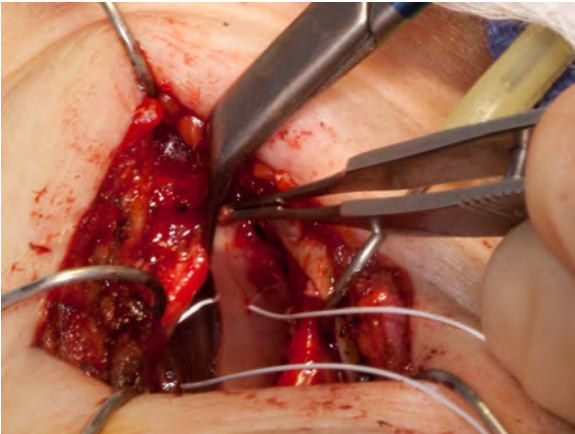
Mark new anterior commissure



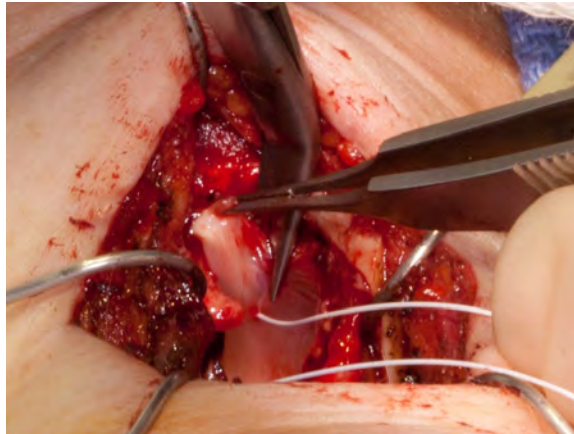
As I stretch the true cords, I use one half of a double-ended CV-5 polytetrafluoroethylene (Gore-Tex) suture to mark the perceived 50% location along the membranous vocal cords as measured from the anterior commissure. I try to include the vocal ligament in this suture to maintain not only a symmetric anterior-posterior length to the neo-vocal cords, but also to maintain the vibratory margins vertical height symmetry. My anticipated goal is to remove about 40% of the anterior membranous vocal cord. With removal of the anterior thyroid cartilage, the anterior-posterior dimension of the larynx will be smaller, so more membranous vocal cord must be removed to raise pitch than in a straight thyrotomy where only a small amount of vocal cord resection will raise pitch to some degree.

TECHNIQUE

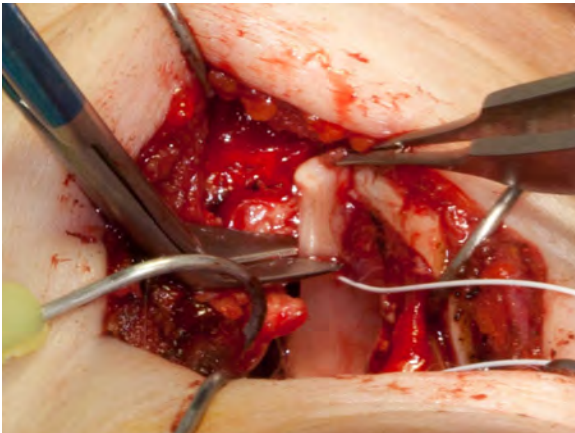
Excise anterior true vocal cord ~ 40% excised



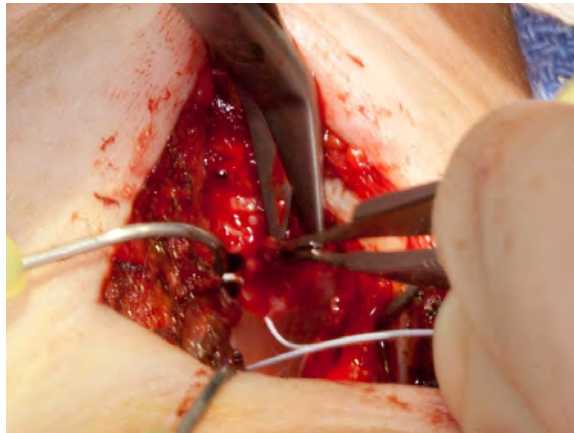
Divide the anterior commissure, minimizing the incision inferior to the vocal ligaments. Keeping the inferior extent of the incision beneath the lower boundary of the thyroid cartilage. A subglottic incision beyond the inferior edge of the thyroid cartilage into the cricothyroid membrane is more difficult to obtain an airtight closure.



While tensioning a cord by grasping the anterior vocal ligament, angled scissors cut through the membranous cord. The mucosal cuts are beveled from lateral to medial. At the lateral aspect the cut is at the edge of the inner lamina of the thyroid cartilage.



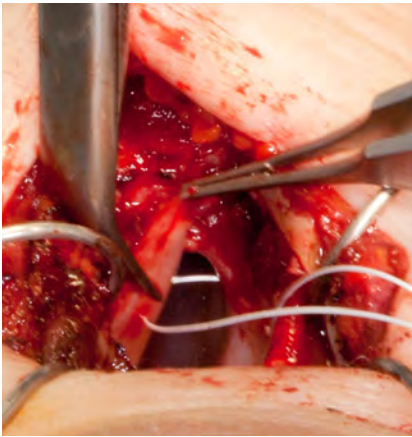
Medially the cut exits the cord just anterior to the marking suture. Mucosa, vocal ligament and the thyroarytenoid muscle are included in the removal.



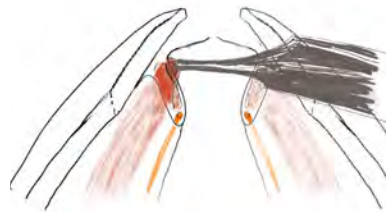Bulky thyroarytenoid muscles may be stretched to remove a bit of additional muscle.

TECHNIQUE

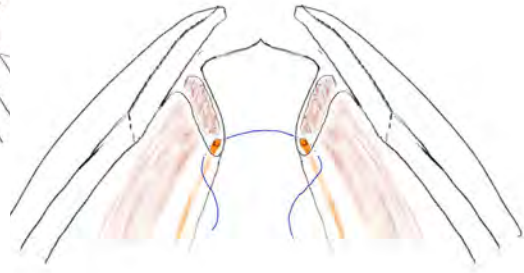Anterior commissure reconstruction



An identical amount is removed from the opposite vocal cord.

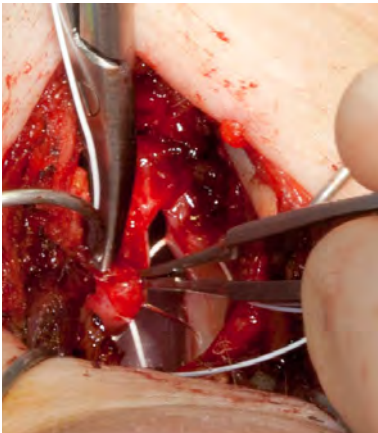

If there seems to be too much muscle bulk, grasp the central thyroarytenoid muscle, place it on a stretch and remove or debulk some additional muscle.

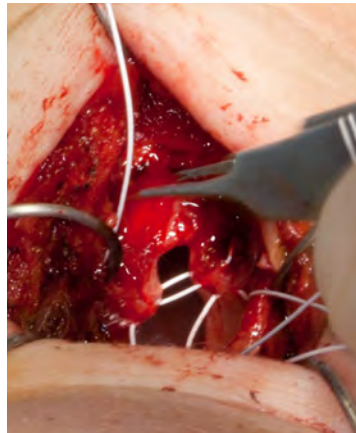


View after true vocal cord reduction.

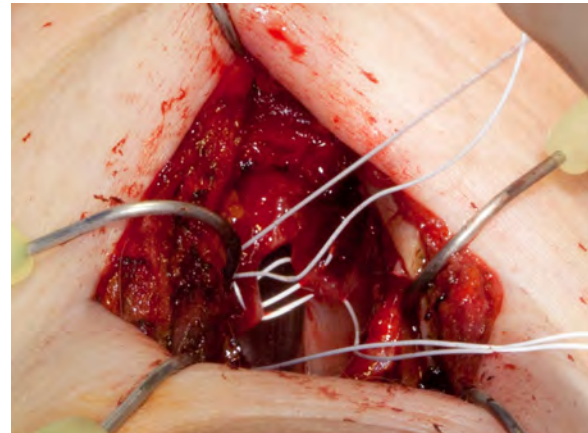
The marking suture can be pulled as the thyroid lamina are brought back together to verify the shortened vocal cords are not too long to be placed under tension when secured against the inner thyroid lamina. If they will not be under adequate tension, then more vocal cord can be removed.



Using a Gore-Tex suture, enter the left thyroarytenoid muscle, passing through the vocal ligament (which feels slightly dense) and includes about 1 mm of medial margin vocal cord epithelium. Attempt to exit at the upper vibratory lip of the membranous vocal cord.



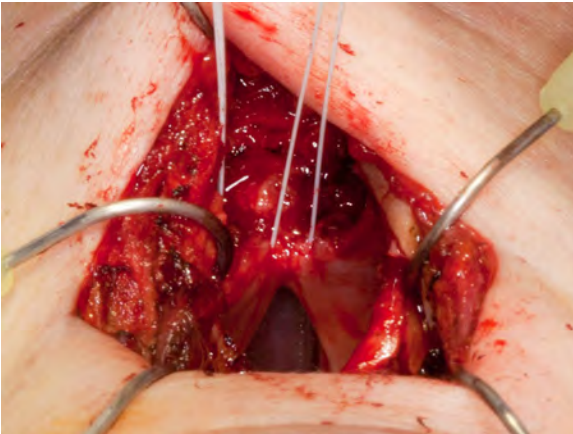
Pass into the opposite cord in a similar location beginning with the vocal cord epithelium and passing into the thyroarytenoid muscle.



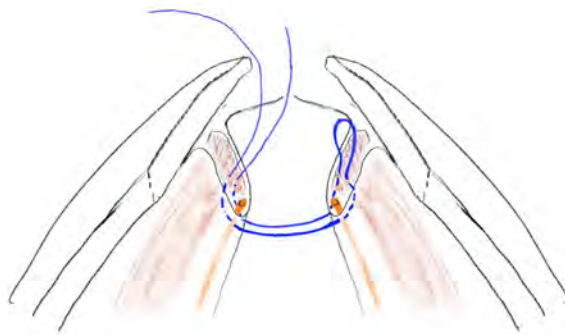
Return the needle back following an inferior path through the inferior vibratory lip of the membranous vocal cord, creating effectively a horizontal mattress suture into the vocal cords.

TECHNIQUE

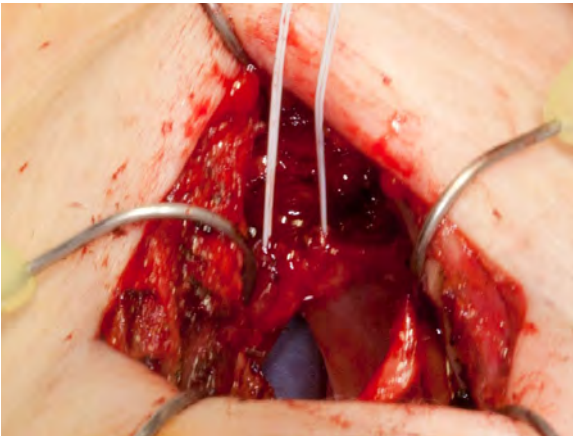
Anterior commissure reconstruction



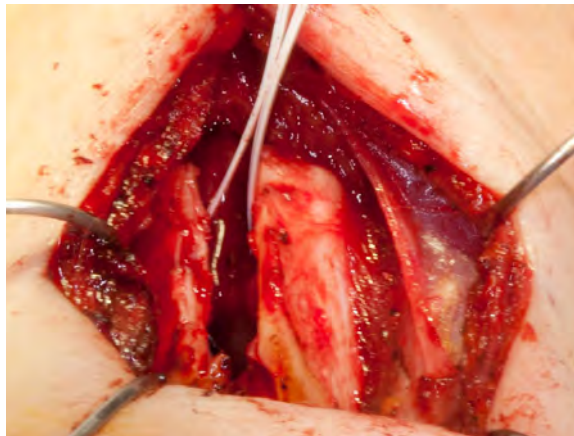
Pulling on the marking suture, visualizes the neo-vocal cords



The marking suture has been removed. Left GoreTex suture in place but not tightened. The cut ends of the thyroarytenoid muscles and vocal ligaments are visible. The GoreTex suture includes about 1 mm of mucosa near the vibratory margin.



The removed marking suture is used as the opposing horizontal mattress suture starting in the right vocal cord, looping through the left and returning to the right. When both of the horizontal mattress sutures are placed, tensioning them should nearly replicate the pull of the marking suture and create a new anterior commissure.

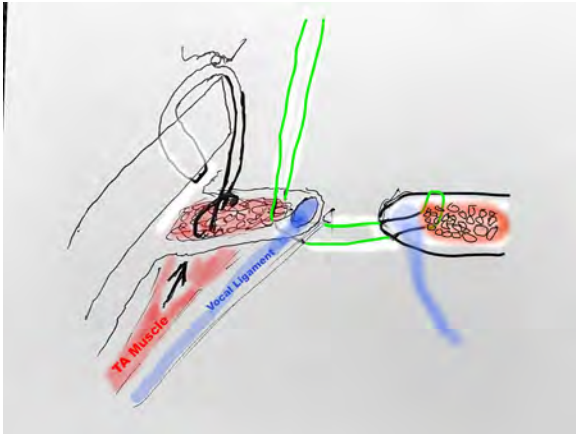


Pulling the anterior commissure sutures while allowing the thyroid alae to come together demonstrates whether tension can be maintained on the shortened vocal cords.

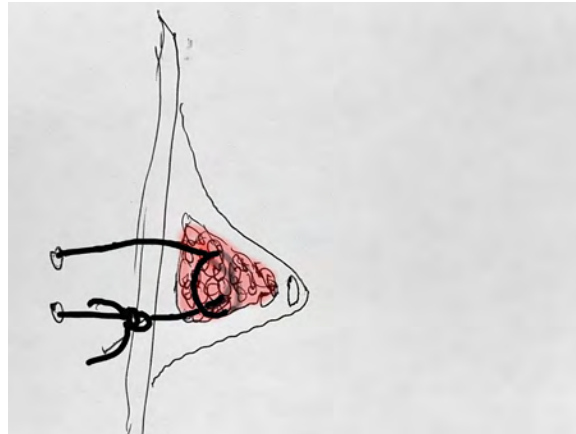
TECHNIQUE

TA muscle tension

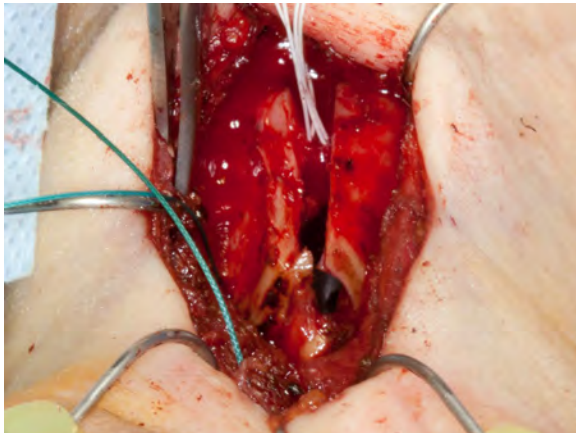
Suture placement



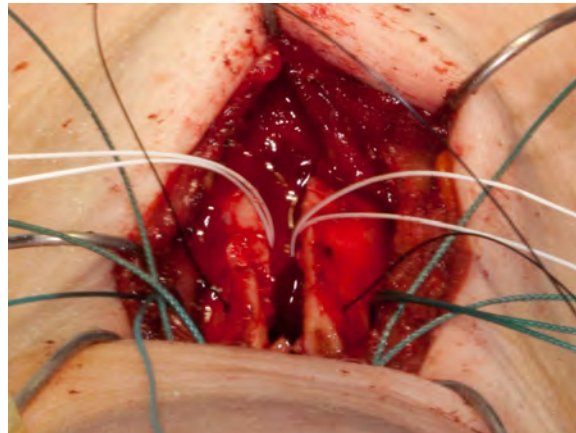
X-sectional view: Additional pull on the TA muscle is helpful to keep the lateral aspect from retracting. After the GoreTex is in place (green suture), I pass a 4-0 Monocryl through the central aspect of the thyroarytenoid muscle and secure it to the exterior of the thyroid cartilage. I loop the monocryl through the muscle twice as muscle doesn't hold a suture as well as other tissue.



Anterior view: Central portion of TA muscle is pulled toward the cut edge of the thyroid cartilage. Suture is secured externally by drilling 1 mm holes in calcified cartilage and passing suture through.



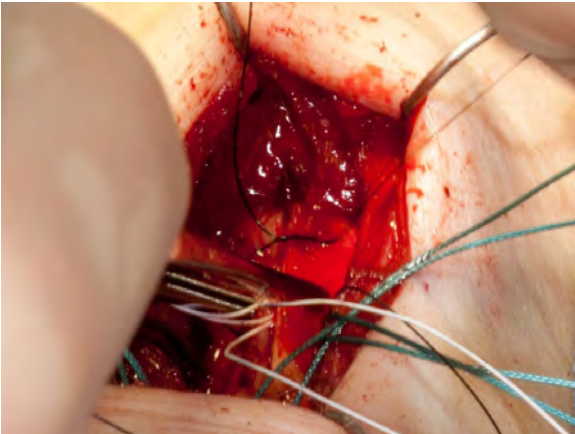
Muscles are elevated from the anterior inferior half of the hyoid bone with electrocautery for 15 mm either side of midline. 4 - 1 mm holes are drilled into the hyoid bone and 2 - 1 mm holes in the superior margin of each thyroid alae. Braided 0-Ethibond sutures are passed through the corresponding holes for later thyrohyoid elevation.



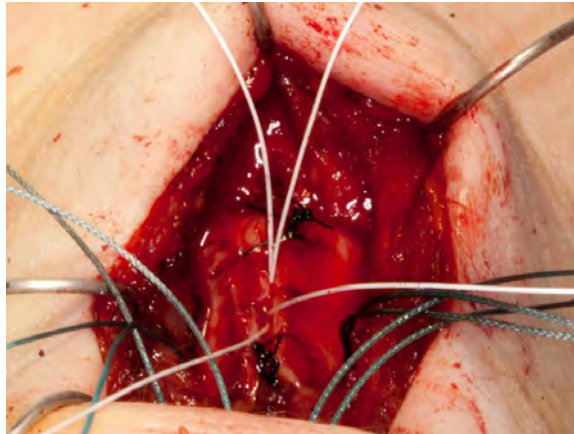
For closure of the thyroid cartilage, two, 1-mm holes are drilled in the new anterior edge of each thyroid cartilage, one inferior at the level of the subglottis, one superior at the level of the false vocal cords. Each hole is angled toward the midline internally. 4-0 Monocryl sutures are passed through the cartilage, then through the cut ends of the false cords and out the opposite thyroid cartilage.

TECHNIQUE

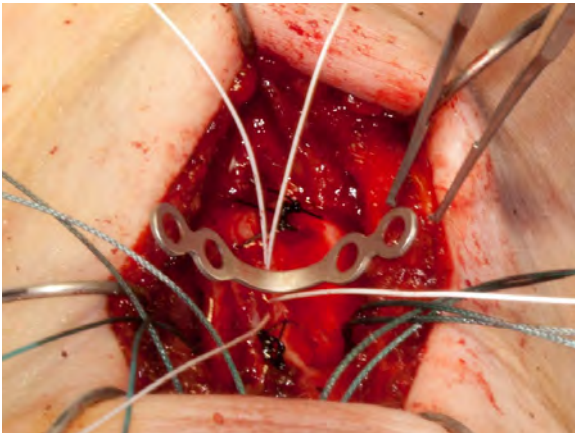
Thyroid Cartilage Closure



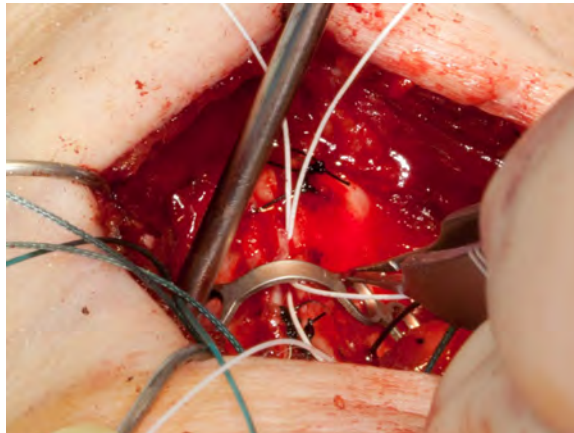
A second 4-0 Monocryl is passed through the inferior hole, through the subglottic cut edges of the inner perichondrium and out the opposite hole. As the thyroid alae are held in approximation with forceps, the sutures are tied.



The inferior suture is secondarily looped through the cricothyroid membrane snugging it up against the thyroid cartilage. The upper suture is passed through the base of the epiglottis and snugged up against the superior border of the thyroid cartilage. These sutures create additional seals preventing post-operative air leak.



A micro-plate is curved to approximate the thyroid cartilage profile.

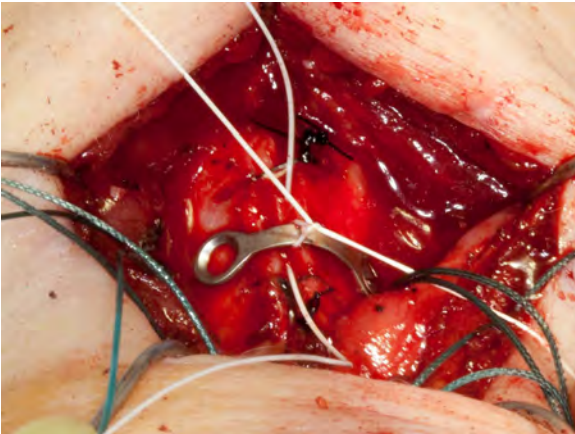


The plate is secured at the location of the anterior commissure with the arms of the Gore-Tex sutures above and below. Three self-tapping, 4 mm screws are sufficient to hold the plate and thyroid cartilage in place.

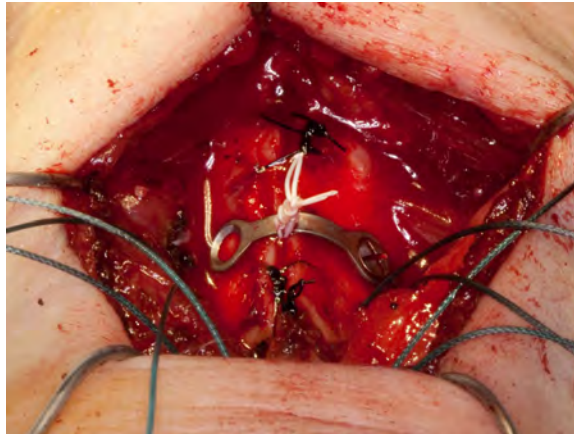
TECHNIQUE

Vocal Cord Tensioning

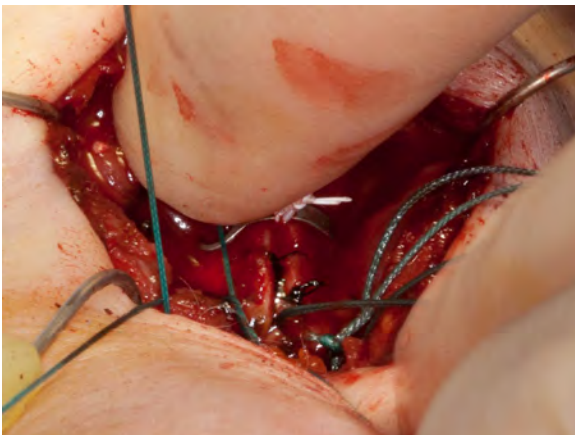
Thyrohyoid elevation



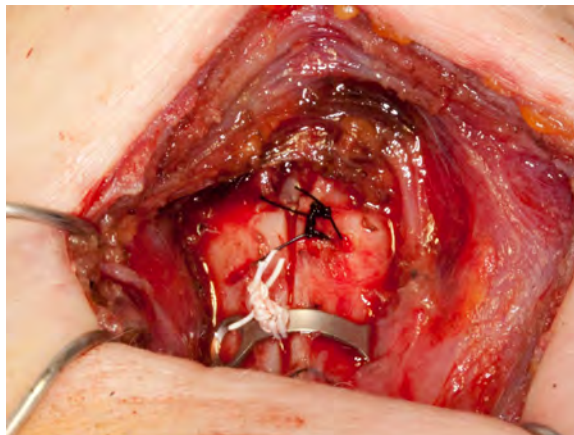
Gore-Tex is slippery enough to slide between even tightly approximated thyroid alae as it is cinched into place over the plate.



With 4 throws on each Gore-Tex, I then tie the pairs of Gore-Tex together with an additional 4 throws, to prevent untying.



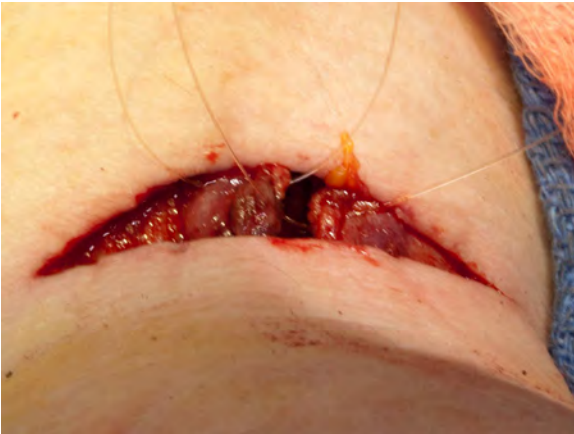The Ethibond sutures pull the thyroid cartilage up close to the hyoid bone when tied, permanently elevating the larynx in the neck.



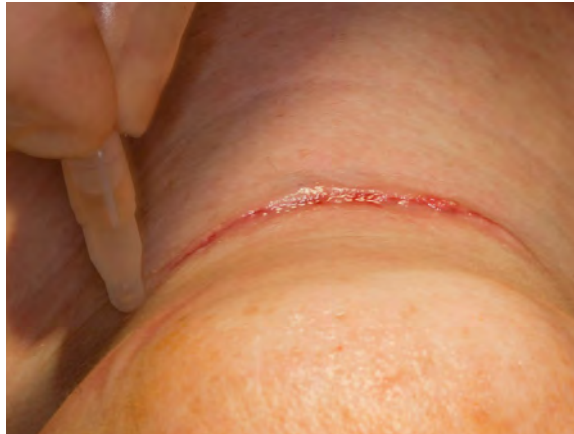Thyroid cartilage positioned higher in the neck. Typically the thyroid cartilage is close to, but does not actually touch the hyoid bone.

TECHNIQUE

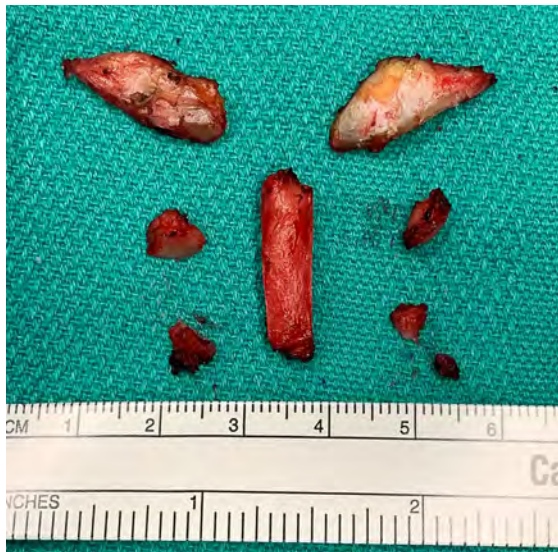Skin closure



The wound is irrigated with saline solution. The strap muscles are reapproximated and can be slightly plicated, pulled superiorly and reattached to the hyoid bone under some tension. Subcutaneous tissues are closed with 4-0 Monocryl.



After a running subcuticular 4-0 Monocryl, cyanoacrylate glue completes the closure.



Cartilage and soft tissue excised during Feminization Laryngoplasty.

- Upper thyroid alae.
- Central thyroid cartilage strut.
- Anterior portions of false vocal cords.
- bAnterior portions of True vocal cords.

Post-operative care

Caveats

POST OPERATIVE

Surgery is performed as an outpatient. Each patient is discharged after approximately one-hour into the care of a friend, family or a professional caregiver. Because of the general anesthetic, she must remain with someone for the first 24 hours postoperatively. Most stay in a nearby hotel of their choosing.

Postoperatively each patient is examined with flexible laryngoscopy every day for three days. Typically, supraglottic swelling is mild the first day, increases on the second day and begins to diminish on the third day.

INFECTIONS & SWELLING

Infections, if occurring, are typically apparent as increasing supraglottic swelling on the third day. They are frequently accompanied by increasing pain and concern on the part of the patient.

The most dangerous area of swelling is the post-arytenoid tissue which, loosely attached to any structure, can swell and be drawn into the laryngeal introitus on inspiration, obstructing the airway.

While true vocal cord swelling may result in very convex vocal cords, even when severe, this does not lead to airway obstruction.

External drainage of any loculation in the wound leads to improvement, but if not done in time, a temporary tracheostomy may be necessary. I placed two tracheostomies when using clindamycin & gentamycin as pre-operative antibiotic coverage. No serious wound infections have occurred since changing to clindamycin & either levaquin or cefuroxime as preoperative antibiotics. The levaquin or cefuroxime is continued orally for 7 days postoperatively. Two hundred cases have been performed as of mid-2019.

Delayed infections are milder and typically respond to antibiotics and removal of infected hardware or sutures.

Swelling is highly variable between individuals. When post-arytenoid swelling is present, steroids are very useful for immediate relief.

RECOVERY

Two weeks of complete voice rest are suggested. Pain is typically fairly minimal (though individually variable). A narcotic is prescribed for use as either pain or cough suppression.

Postoperative instructions include instructions to avoid coughing. However, one patient felt that she couldn't breathe, yet endoscopy revealed a good glottic airway. She later coughed out a clot of blood from her lungs and her air hunger resolved immediately. Consequently I advise patients to cough when needed even though this stresses the vocal cords. If coughing occurs frequently from a tickle, then I recommend they suppress the cough with the narcotics.

More commonly patients experience the sensation of needing to clear the throat which is not relieved by throat clearing. I suspect this is a sensation generated by the swollen vocal cords touching each other, giving the sense of something on the vocal cords.

Nothing heavier than 10 pounds is to be lifted for one month. Other forms of straining, such as Valsalva maneuver, are strongly discouraged.

I ask that she not be electively intubated for a period of three months. If intubated for general anesthesia she should request a number 6 endotracheal tube be used.

POST EVALUATION

Acoustic and videolaryngeal evaluations are performed whenever patients return.

Voice samples are also accepted from distant patients who complete a recording by reading a voice analysis script. This includes conversation voice, maximum phonation time, highest and lowest pitch and loud and soft voice use.

CAVEATS & THOUGHTS

ANESTHESIA

My initial FemLar procedure was performed under local anesthesia. Although this is a feasible approach in terms of minimal pain during and after the surgery, the seeming risk of tearing the vocal cords while suturing them, if the patient tries to speak at an inappropriate

moment, seems to outweigh the benefits of this approach. After the first patient, general endotracheal anesthesia was used largely to prevent vocal cord movement at an inappropriate time.

DIVIDING THE CARTILAGE

The thyroid cartilage is not calcified in some young patients and a knife may be used. Over my series of patients, I placed the cuts further and further laterally trying to further narrow the larynx, until in one patient, after removing 10 mm either side of midline, I could not approximate the inferior cut edge of the thyroid cartilage. The upper edge of the cricoid cartilage lies internal to the lower thyroid cartilage and the external diameter of the cricoid cartilage precluded complete closure.

Currently, the vertical incisions in the thyroid cartilage are generally placed about 4 to 5 millimeters either side of the midline. The amount removed varies with the perceived size of the thyroid cartilage. In very large thyroid cartilages and in cartilages with a very acute anterior angle the vertical thyroid cartilage incision tends toward 7 millimeters from the midline. In small or very flat thyroid cartilages, perhaps only 3 millimeters are removed. At the typical beveled angle, in the average person, this removed piece of cartilage measures about 5 millimeters in width. The width or kerf of the saw blade itself is about 1 mm.

REVISIONS

Revisions are possible. In my first patient I conservatively removed additional vocal cord over three surgeries until we reached the pitch that she desired. I presently consider about 40% of membranous cord to be the appropriate amount to remove.

PRIOR CTA SURGERY

If a patient had a prior CTA surgery, the cricoid and thyroid cartilage are typically fused. Even if they can be pried apart or even if they are sawed apart, in my experience, the cricothyroid joint has typically been immobilized long enough that the joint is non-functional. The cricothyroid muscle can no longer modify the vocal cord length. Dissecting apart this fusion sometimes lowers the pitch

back into a male speaking range: certainly not desirable in most cases. Consequently, if there has been a prior cricothyroid approximation, I leave the approximation intact. I utilize a midline thyrotomy division and do not remove any additional thyroid cartilage. The cricothyroid fusion limits opening of the thyroid cartilage and surgical exposure. I try to gain additional pitch elevation solely through removal of anterior membranous vocal cord and typically remove about 20% of the length.

Taking apart a cricothyroid fusion from a prior CTA however, may not be a reliable way to lower the pitch, again because of cricothyroid joint fixation. There is an uncommon patient wishing to return to a lower or male speaking pitch. If after taking apart a cricothyroid fusion under local anesthesia, there is no or insufficient pitch drop, I place two vertical thyrotomy incisions and remove one to 3 mm of cartilage from one or both sides which drops the tension in the vocal cords.

This issue of cricothyroid joint fusion is also the reason I discourage "trying the CTA surgery first". The CTA procedure causes loss of use of one of the most important muscles for elevating pitch. The postoperative CTA patient has only the thyroarytenoid muscle remaining to change pitch. The postoperative FemLar patient has both a shortened thyroarytenoid muscle available as well as a cricothyroid muscle available to alter pitch.

DIVIDING THE VOCAL CORDS

In early cases, I divided the anterior commissure early in the procedure so that I could widely open the larynx for a view. The very first time I cut the membranous vocal cords, the mucosa contracted all the way back to the vocal process, an unsettling maneuver that makes the vocal cord seem to disappear. It is possible to re-grasp the mucosa and the vocal ligament. However, resecting the anterior vocal cord one at a time seemed also to be a possible contribution to the likelihood of postoperative asymmetry between the vocal cords.

Thus, I now place the marking suture in the mid-portion of the vocal cords in everyone before removing the anterior vocal cords. It acts as a marker for where I intend to place a cut as well as the suture to maintain symmetry. I place the cut just anterior to the marking suture. Then I place the first horizontal mattress suture, defining the new anterior commissure before removing the marking suture. This also defines for me the area of the vocal ligament. When the vocal cord is cut, it not only contracts posteriorly toward the vocal ligament, it flattens out against the lateral aspect of the thyroid cartilage. It can be difficult to locate the vertical level of the vocal ligament after releasing it.

VOICE REST

With the initial patients I did not suggest any voice rest. Many patients when they initially speak have a deeper comfortable speaking pitch, presumably because of the easily visualized swelling of the transected vocal cords. Some patients seem to have tight enough vocal cords with minimal swelling

and have a higher pitch even the first week after surgery. One patient, with an initial great result, began singing one week after surgery. She felt a pop and noted that her comfortable speaking pitch dropped. Since that time, I have requested two weeks of voice rest and a number of patients have voluntarily undergone three weeks of voice rest if their occupation allowed.

SUBCUTANEOUS EMPHYSEMA

This results from lack of an airtight closure or from an aggressive cough. Some patients will feel a need to cough from a tickle, or to clear secretions, or to clear a blood clot from the internal incision or even from a sensory illusion, the result of the swelling that places the anterior cords in apposition to each other. Isolated or infrequent coughing does not necessarily cause a problem. However, heavy or ongoing coughing may lead to subcutaneous emphysema. I have managed this with observation or on a rare occasion with placement of a drain. If air is leaking from internally, there also seems to be a higher associated rate of infection.

POSTOPERATIVE AIRWAY COMPROMISE

All of the airway compromise I have seen has been from supraglottic edema and principally from edema on the posterior aspect of the arytenoids. Edema seems to peak on postoperative day number 2. Infections seem to be identifiable by day three or else an infection tends not to occur. I have not seen any airway compromise from edema at the level of the glottis either early or late.

After one infection, where I inadequately drained a subcutaneous collection of purulence, the following day I placed a temporary tracheostomy and drained a deeper collection of purulence beneath the strap muscles. For a number of patients after this I then placed a drain at the time of skin closure. This drain seemed to make no positive difference in the rate of infection and perhaps increased the rate of infection, so I have not been placing drains since. After switching preoperative antibiotics to a combination of clindamycin and a third generation cephalosporin, combined with 7 days of postoperative cefuroxime or levofloxacin, I have encountered no severe infections.

I very aggressively try to ensure an airtight closure of the incision into the larynx. My present management approach is that if on endoscopic examination on postoperative day number two or number three there is any suggestion of infection including either supraglottic edema, supraglottic erythema, increasing pain, subcutaneous fullness or subcutaneous fluid collection then I will treat aggressively for presumed infection. This includes needle aspiration of any potential subcutaneous fluid collection, culture and oral antibiotics.

In all cases of infection persisting beyond ten days, I have ultimately returned the patient to surgery and removed the hardware or suture that was associated with the ongoing infection. The plate and GoreTex sutures, if removed after one month, are no longer needed and the anterior commissure remains well attached.

ASYMMETRY

I noticed varying degrees of asymmetry of the vocal cords on stroboscopy of patients from my very first procedure. While sometimes asymptomatic, there can be some pitch where asymmetric cords cause dysphonia, specifically diplophonia. If this is at the comfortable speaking pitch, the patient may learn to elevate or lower the pitch slightly to avoid the rough spot. Initially, when severe enough, I tried to correct the asymmetric tension with a revision surgery.

16 of the first 31 patients received a revision surgery for roughness, huskiness or inadequate pitch elevation. Asymmetry correction was difficult to accomplish with scar tissue from the initial surgery being present and it was difficult to judge the exact amount to remove.

On one patient with particularly severe dysphonia after an infection, I utilized an office PDL laser to create a burn on the superior surface of the looser vocal cord, which tightened, correcting the dysphonia. It also raised the pitch slightly.

Since then, I have used first the pulsed dye laser, then the KTP laser for vocal cord tightening. Using a flexible laser fiber passed through a flexible laryngoscope has proven to be a very cost effective means of correcting surgical asymmetries.

The laser can also be applied bilaterally to raise the pitch. If I tighten both sides, I frequently can obtain an additional semi-tone of pitch elevation. This office laser procedure may be repeated after two to three months. I don't know the limit of how much pitch elevation may be obtained with additional treatment(s).

From patient 32 through 200 I have done an additional 15 revisions. Most problems of asymmetry or insufficient pitch elevation may be treated with either the office laser for smaller problems or with microlaryngoscopy and the CO2 laser to remove larger quantities of tissue avoiding a complete revision.

RESONANCE

On the first patient which I tried a thyrohyoid elevation, I was able to elevate the larynx just by passing sutures through the upper thyroid cartilage and the hyoid bone, but in my second patient and in many patients since, the upper edge of the thyroid cartilage abuts the hyoid bone precluding additional elevation. Since then I remove 8-10 mm of upper thyroid cartilage, which gives additional room to raise the larynx in the neck. It also gives the appearance during surgery of a more typical female sized thyroid cartilage.

Elevation of the larynx changes only one of several anatomical features that contribute to resonant frequency. Other anatomical differences that affect resonance (ie. the sinuses) cannot easily be surgically manipulated to produce a more feminine resonance.

One anatomic area that might also be surgically manipulated is the diameter of the pharynx. There may be a way to plicate the pharyngeal walls and narrow the

circumferential dimension of the pharynx, improving resonance of higher pitches. Or perhaps one might devise a subcutaneous augmentation to narrow the pharyngeal diameter in a way analogous to an obese person's narrowed pharynx.

Most patients note a loss of volume, both in everyday speech and for a yell. In most cases she cannot replicate the volume of her previous voice. Subjectively, some patients are pleased with the softness of their new voice or may consider it a reasonable trade-off.

VOICE RECORDINGS

One patient was very upset to have spent so much money and there was no change in her voice. She never followed up. 4 years later I contacted her and she was not interested in speaking she was so unhappy with the result. A few months later, a business trip brought her to Portland and she stopped in. I recorded her voice and played her preoperative voice to her for comparison. She not only sounded feminine, but she was amazed at the difference.

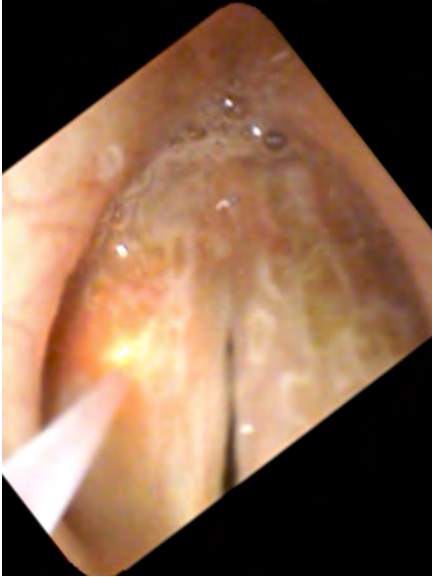Numerous patients do not perceive the

change in their voice after surgery. I suspect we are used to hearing our voice via internal bone conduction. Additionally FemLar does not change the accent nor character of the voice after surgery. While documentation is important in many respects (for the surgeon to learn what works, legal documentation, etc.), it is invaluable to the patient as well to hear the difference in voice after surgery by listening to recordings. After hearing the pre and post-operative recordings, many patients gain confidence in her new voice.

Bibliography

1. Wagner I, Fugain C, Monneron-Girard L, Cordier B, Chabolle F (2003) Pitch-Raising Surgery in Fourteen Male-to-Female Transsexuals. *Laryngoscope* 113:1157-1165 doi: 10.1097/00005537-200307000-00011
2. Brown M, Perry A, Cheesman AD, Pring T (2000) Pitch Change in Male-to-Female Transsexuals: Has Phonosurgery a Role to Play? *Int J Lang Comm Dis* 35:1:129-136 doi: 10.1080/136828200247296
3. Isshiki N, Morita H, Okamura H, Hiramoto M (1974) Thyroplasty as a New Phonosurgical Technique. *Acta Otolaryng* 78:1:451-457 doi: 10.3109/00016487409126379
4. Isshiki N, Taira T, Tanabe M (1983) Surgical alteration of the vocal pitch. *Otolaryngol Head Neck Surg* 5:3:35-40
5. Isshiki N (1998) Mechanical and dynamic aspects of voice production as related to voice therapy and phonosurgery. *Journal of Voice Jun*; 12(2):125-37
6. Neumann K, Welzel C, Berghaus A (2003) Operative voice pitch raising in male-to-female transsexuals. A survey of our technique and results HNO. *Jan*; 51(1):30-7
7. Matai V, Cheesman AD, Clarke PM (2003) Cricothyroid approximation and thyroid chondroplasty: a patient survey. *Otolaryngol Head Neck Surg Jun*; 128(6):841-7
8. Yang CY, Palmer AD, Murray KD, Meltzer TR, Cohen JI (2002) Cricothyroid approximation (CTA) to elevate vocal pitch in male-to-female transsexuals: results of surgery. *Ann Otol Rhinol Laryngol Jun*; 111(6):477-85
9. Tucker, HM (1985) Anterior commissure laryngoplasty for adjustment of vocal fold tension. *Ann Otol Rhinol Laryngol* 94:547-9
10. Donald PJ (1982) Voice change surgery in the transsexual. *Head Neck Surg May-Jun*; 4(5):433-7
11. Gross M (1999) Pitch-Raising Surgery in Male-to-Female Transsexuals. *J Voice* 13:2:246-250
12. Remacle M, Matar N, Morsomme D, Veduyck I, Lawson G (2011) Glottoplasty for male-to-female transsexualism: voice results. *J Voice Jan*; 25(1):120-3
13. Hong KH, Ye M, Kim YM, Kevorkian KF, Kreiman J, Berke GS (1998) Functional differences between the two bellies of the cricothyroid muscle. *Otolaryngol Head Neck Surg May*; 118(5):714-22
14. Orloff L, Mann A, Damrose J, Goldman S (2006) Laser-Aided Voice Adjustment (LAVA) in Transsexuals. *Laryngoscope* 116:655-660 doi: 10.1097/01.mlg.0000205198.65797.59
15. Neumann K, Welzel C (2004) The importance of the voice in male-to-female transsexualism. *J Voice Mar*; 18(1):153-67
16. Koçak I, Akpınar ME, Cakır ZA, Doğan M, Bengisu S, Celikoyar MM (2010) Laser reduction glottoplasty for managing androphonia after failed cricothyroid approximation surgery. *J Voice Nov*; 24(6):758-64
17. Dacakis G (2000) Long-term maintenance of fundamental frequency increases in male-to-female transsexuals. *Voice* 4:549-556
18. Wolfe VI, Ratusnik DL, Smith FH, Northrop G (1990) Intonation and fundamental frequency in male-to-female transsexuals. *J Speech Hear Disord* Feb; 55(1):43-50
19. Lawrence, A (2004) <http://www.annelawrence.com/twr/voicesurgery.html>
20. Günzburger D (1989) Voice adaptation by transsexuals. *Clin Linguist Phon* 3(2):163-72
21. Carew L, Dacakis G, Oates J (2007) The effectiveness of oral resonance therapy on the perception of femininity of voice in male-to-female transsexuals. *J Voice Sep*; 21(5):591-603
22. Kunachak S, Prakunhungsit S, Sujjalak K (2000) Thyroid cartilage and vocal fold reduction: a new phonosurgical method for male-to-female transsexuals. *Ann Otol Rhinol Laryngol Nov*; 109(11):1082-6

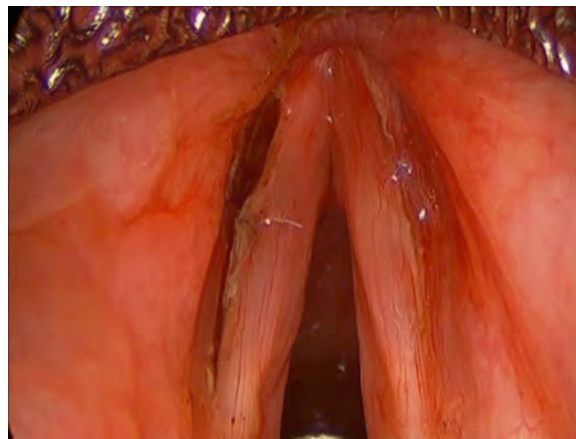
FINAL THOUGHTS



KTP tightening: Office KTP laser tightening of the superior true vocal cord surface.

A process toward a goal

At times a single procedure is successful in converting the voice from masculine to feminine, but the various surgical procedures to change the voice as well as speech therapy can be considered tools that are useful in different situations and sometimes more than one tool is necessary for a successful outcome.



CO₂ reduction: Surgical CO₂ laser reduction of thyroarytenoid muscle and suturing true vocal cord mucosa laterally.

Conclusion

Feminization laryngoplasty, including thyrohyoid elevation and possibly a later postoperative laser tuning, are surgical techniques designed for individuals wishing to transition from a male to female voice by increasing the fundamental and resonant frequencies of her voice.

The typical patient goal is that the voice stands on its own without other cues. Consequently many define success as being recognized as female on the telephone.

A higher bar reached by some patients is

the inability to sound male. Without thinking about voice production, the relaxed sound is feminine. Consequently the individual transitions to feeling female rather than feeling like a transgender female.

Although the principles of the Feminization Laryngoplasty procedure are straightforward there are a number of details important for successful outcomes. Many of the details are included here, although there likely is a feel to how much tissue to remove in each individual, how tight to pull on a suture and other surgical judgements.